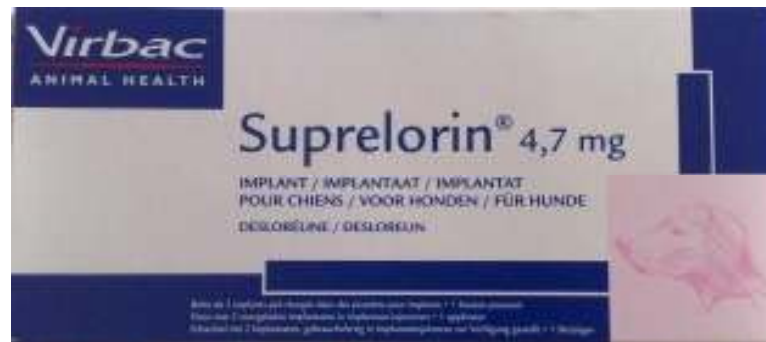



**DO DESLORELIN IMPLANTS
(SUPRELORIN®) OFFER GREAT PERSPECTIVES
FOR TEMPORARY SUPPRESSION OF OVARIAN
FUNCTION IN BITCH AFTER NON-SURGICAL
TREATMENT OF PYOMETRA**

Plamen Georgiev PhD

Anatoli Atanasov

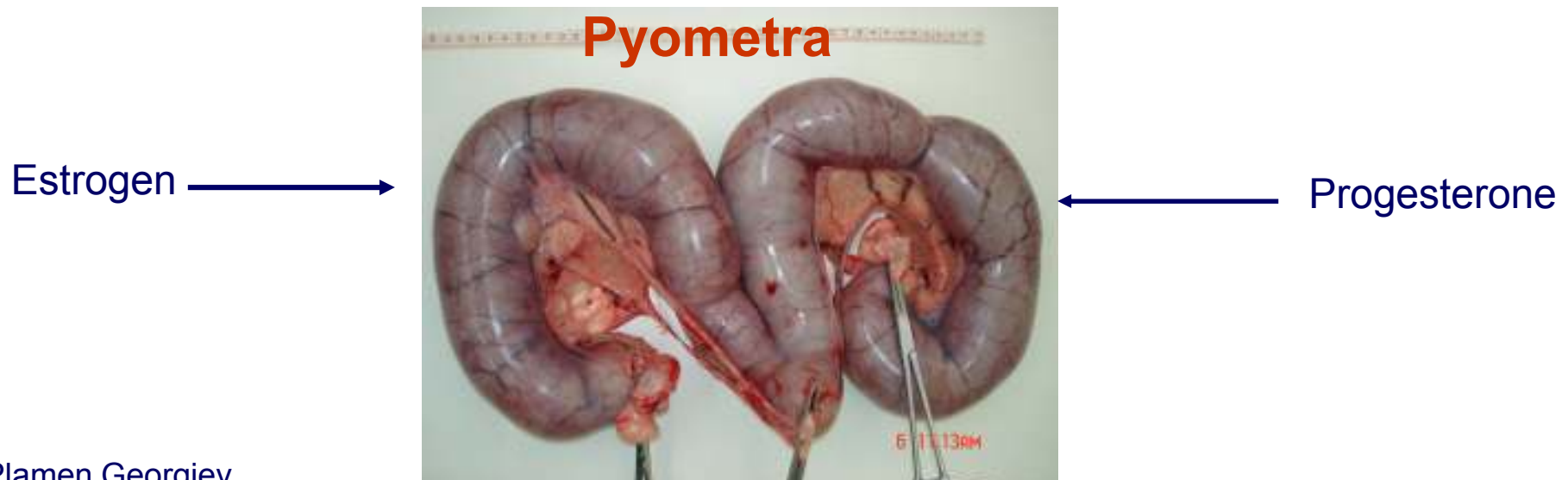
Suprelorin® - Pyometra- Bitch

Introduction

- Pyometra is a common disease of the uterus, most commonly seen in female dogs.
- Pyometra is typically secondary to pathologic changes induced in the endometrium from progesterone exposure over heat cycles (Hardy 1974).
- The progestogen effect is enhanced by priming of the endometrium with estrogen (Johnston et al. 2001).
- Follow-up of animals after treatment of pyometra is important.
- The probability of recurrence of the disease after medical treatment varies between 10-70 % in different studies (Wiebe 2009, Hagman 2010).

Suprelorin® - Pyometra- Bitch

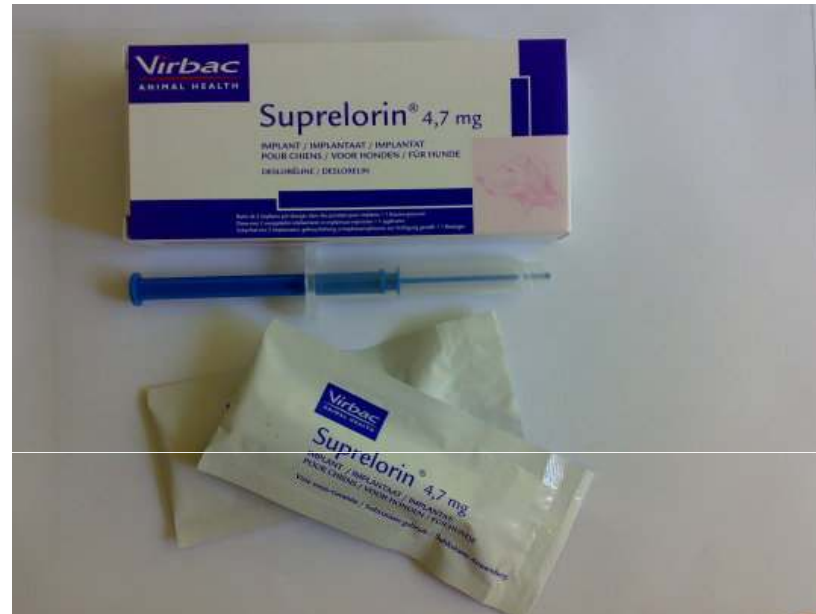- Estrus suppression after conservative treatment of pyometra, with a subsequent decline in exposure of the endometrium to estrogen followed by progesterone, may prevent recurrence of the disease.



Suprelorin® - Pyometra- Bitch

- During the last decade application of depot GnRH-agonist implanten for the suppression of heat in the bitch came into focus of veterinary research.
- Because of the risk of metropathy the implant Suprelorin® should not be used in older bitches (Palm and Rechler 2010).

Suprelorin® - Pyometra- Bitch



Sexual hormones deactivated

But all sexual hormones ?

Suprelorin® - Pyometra- Bitch

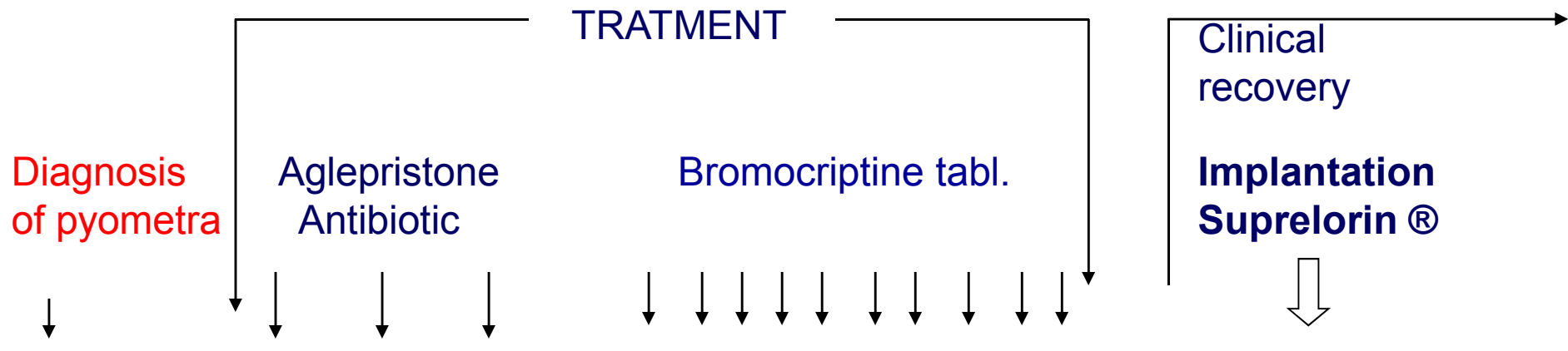
Aim

- Do slow-release deslorelin implants provide efficacious and safe for the prevention of recurrence of the pyometra in female dog ?

Suprelorin® - Pyometra- Bitch

Material and methods

- 9 bitches with ultrasonographically diagnosed spontaneous pyometra

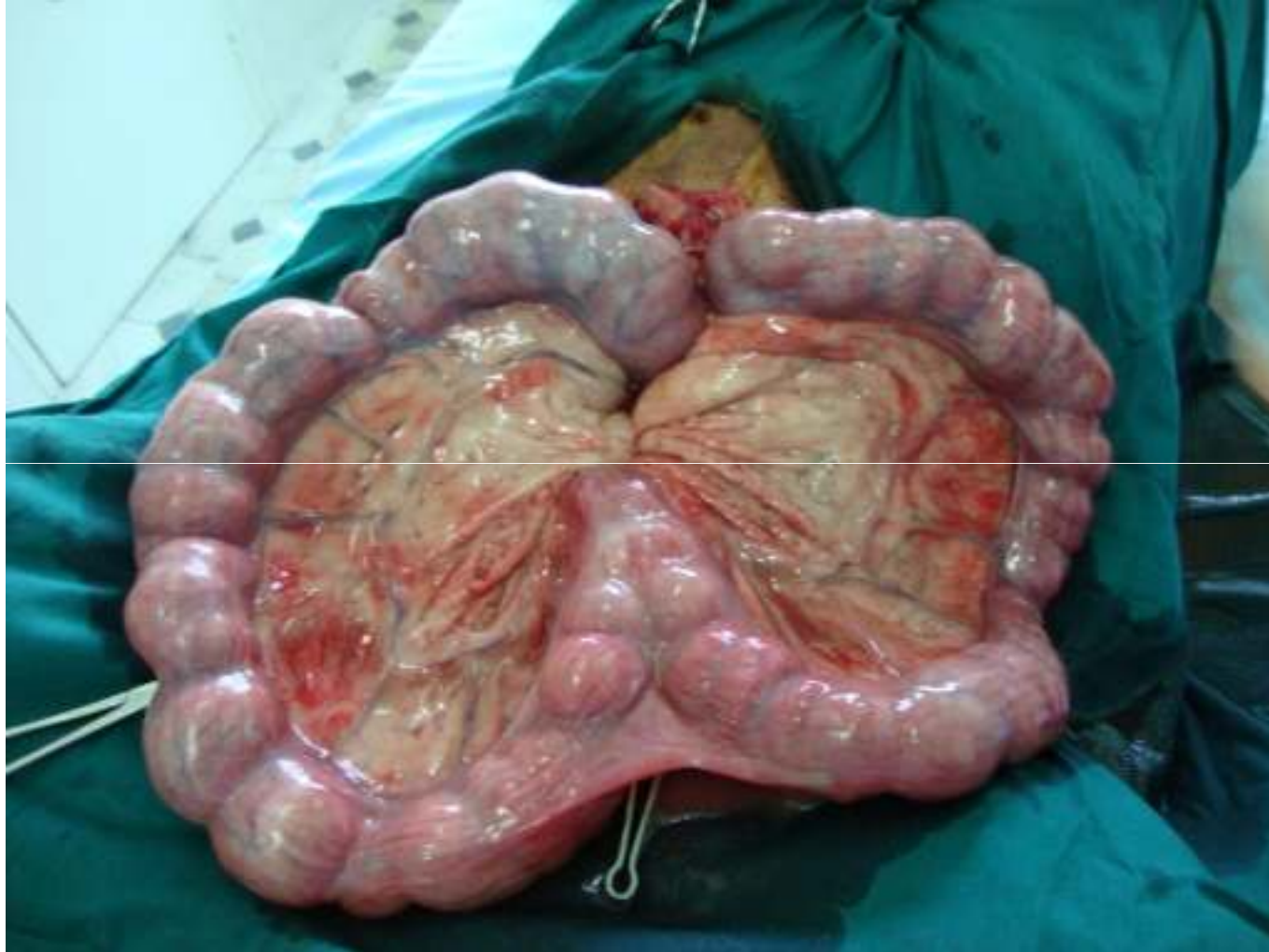

Suprelorin® - Pyometra- Bitch

Results

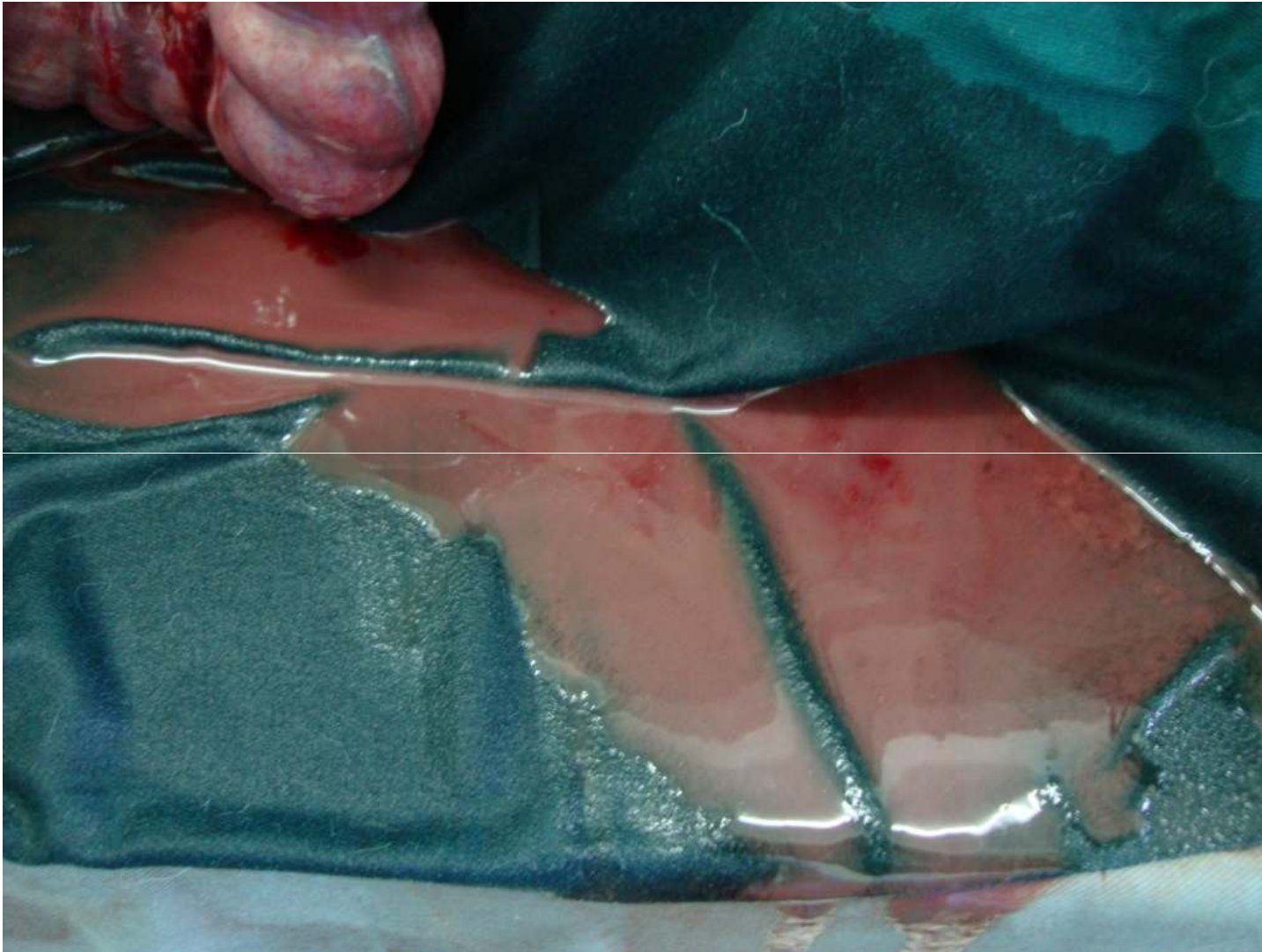
- Until ~ 2 years after implantations in 2 bitch pyometra was recurred. In these two cases:
 - the pyometra were open;
 - the dogs were submitted to ovariohysterectomy (OHE);
 - large amount of odourless red-brown fluid in the abdomen were detected;
 - the uterus were intact;
 - peritoneum was coarsened and bold.

Suprelorin® - Pyometra- Bitch



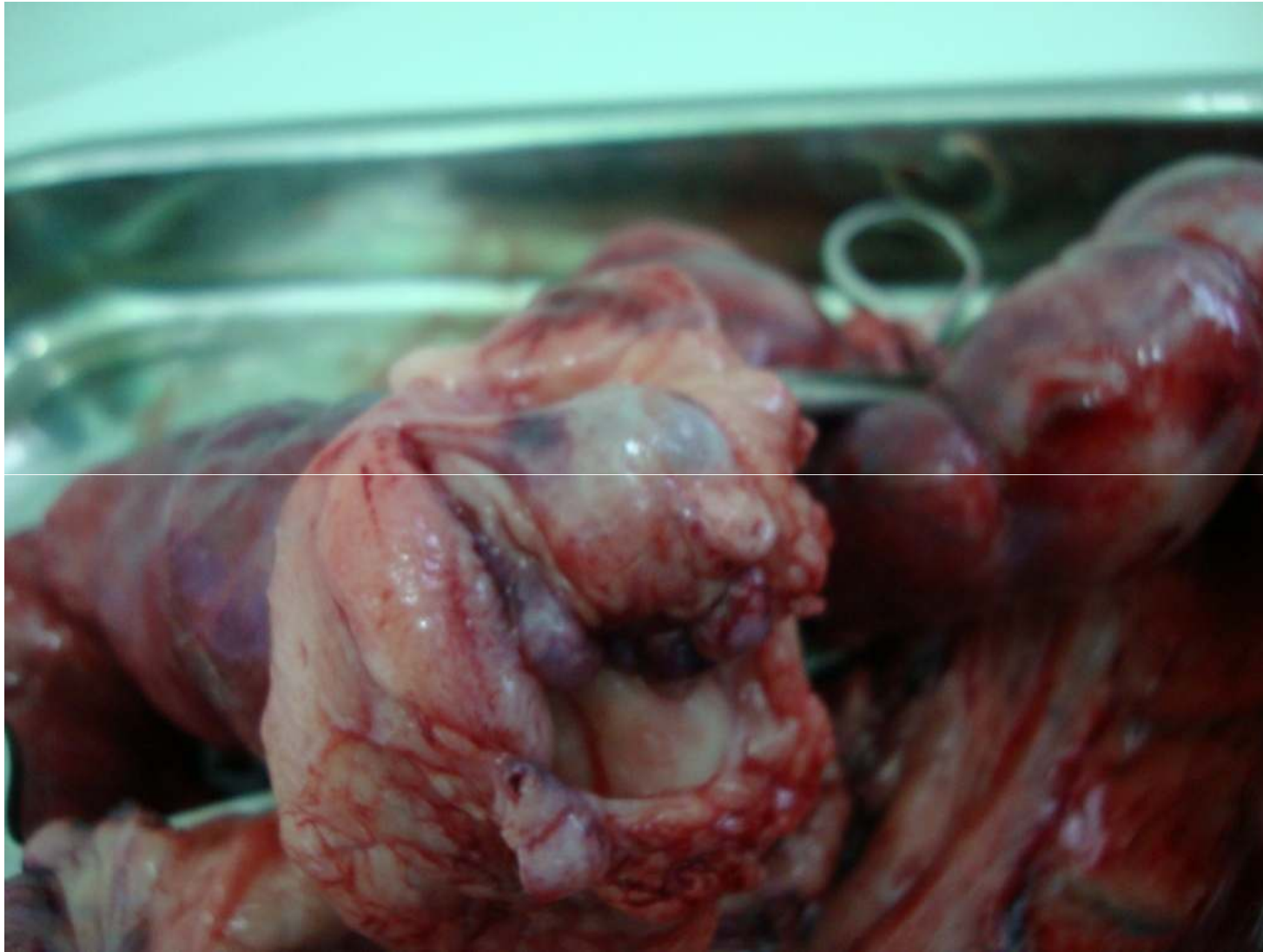Uterus by operation ! Typically pyometra !

Suprelorin® - Pyometra- Bitch



Large amount of odourless red-brown fluid in the abdomen !
Plamen Georgiev
September 2011

Suprelorin® - Pyometra- Bitch



Follicular cysts were diagnosed at ovaries

Plamen Georgiev
September 2011

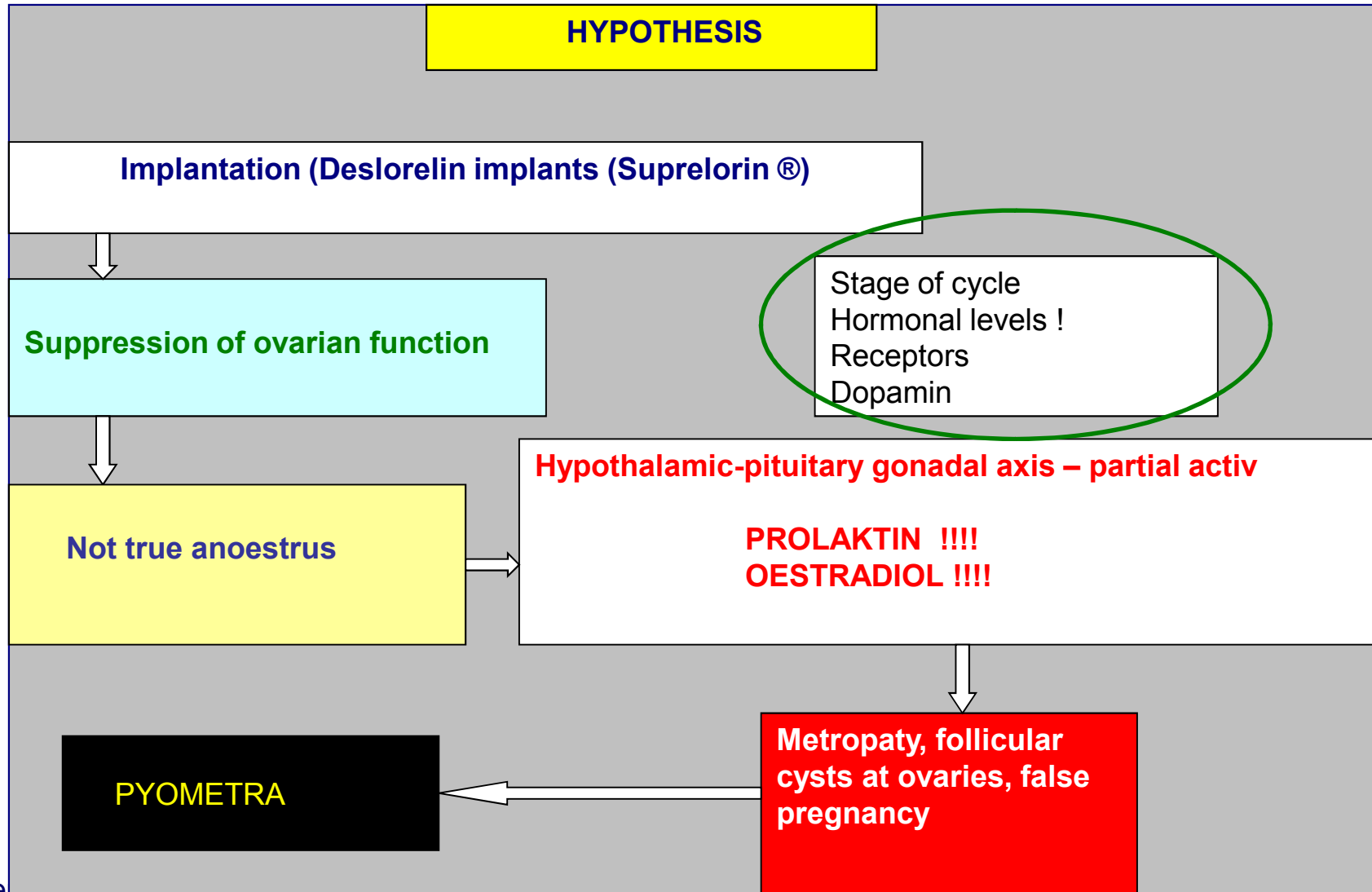
Suprelorin® - Pyometra- Bitch

After surgery the animals recovered rapidly !



Suprelorin® - Pyometra- Bitch

Discussion



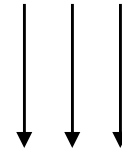
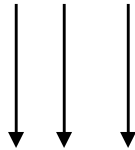
Suprelorin® - Pyometra- Bitch

Discussion

HYPOTHESIS

What would be happened if:

**Implantation
Suprelorin®** → Was followed by twice a year - a course of treatment with
dopamine agonist drugs



Suprelorin® - Pyometra- Bitch

TO BE CONTINUED

